


**PATIENT**  
 Bauer Wolf

**PRESENTING CLINICAL SIGNS**  
 History: Grade 5/6 heart murmur.

**SPECIES**  
 Canine

**BREED**  
 Rottweiler

**SEX**  
 Male Intact

**AGE**  
 3 months

**ECHOCARDIOGRAM FINDINGS**

2D, m-mode, color flow and doppler imaging is available. Mild thickening of the mitral valve with no obvious prolapse into the left atrial lumen. Mild anterior-directed mitral regurgitation. Normal left atrial dimension. Normal LV diameter with normal myocardial function. The LV wall thickness is mildly increased (1.0cm). Diffuse endocardial fibrosis and remodeling. Subaortic narrowing is visualized. The tricuspid valve appears mildly thickened with trace TR. Mild right atrial dilation. Moderate right ventricular hypertrophy and remodeling indicative of pressure overload. Right ventricle is mildly dilated. Pulmonic outflow velocities are elevated, although the level of the obstruction cannot be visualized. PV is thickened, although not extensively evaluated. Mild PI. There is mild post-stenotic dilation of the main pulmonary artery and branches. Moderately elevated aortic outflow velocity. The aortic valve appears globally thickened. Marked aortic insufficiency. No obvious cardiac shunts are present. No pericardial or pleural effusion noted.

**CARDIAC CHART**
**WEIGHT**  
 20.3lbs

CANINE CARDIAC PARAMETERS	MR VMAX (m/s)	TR VMAX (m/s)	LA/AO (Boon method)	LA/AO (Heart Base; Swe)	FS (%)	EF (%)	EPSS (cm)
NORMAL PARAMETER	4.5-5.5	<2.7	1.3	<1.6	28-40	40-100	<0.6
PATIENT	NM	3.0	1.8	1.1	27	50	NM
CANINE CARDIAC PARAMETERS	HR (BPM)	AV VMAX (m/s)	PV MAX (m/s)	BODY WEIGHT (kg)	LA 2D short axis Base view (cm)	LVIDd Avg: 2D and m-mode short axis (cm)	LVIDs Avg: 2D and m-mode short axis (cm)
NORMAL PARAMETER	50-100	0.7-1.7	0.7-1.6	BELOW	BELOW	BELOW	BELOW
PATIENT	174	3.9	4.3	9.2	2.1	2.6	1.9
*Normal chamber parameters expressed as a mean value (SD)				3	1.27 (5.3)	2.46 (2.46)	1.36 (5.5)
<b>BODY WEIGHT DEPENDENT PARAMETERS</b>				5	1.40 (4.5)	2.74 (5.2)	1.60 (4.7)
<i>*Note: All measurements based upon multi-modal images and methods. An average value is reported.</i>				10	1.50 (3.8)	3.27 (3.5)	2.06 (3.1)
				15	1.83 (2.0)	3.71 (2.4)	2.43 (2.1)
				20	2.02 (1.9)	4.14 (2.2)	2.80 (2.0)
				25	2.18 (2.4)	4.48 (2.9)	3.10 (2.5)
				30	2.33 (3.3)	4.83 (3.9)	3.39 (3.4)
				35	2.48 (4.3)	5.17 (5.0)	3.69 (4.5)
				40	2.62 (5.2)	5.48 (6.1)	3.96 (5.4)
				50	2.88 (7.1)	6.07 (8.3)	4.46 (7.4)

**INTERPRETED BY**  
 Maggie Machen Lamy,  
 DVM DACVIM  
 (Cardiology)

**IMAGING PERFORMED BY**  
 Kelly Reschny, RVT

**HOSPITAL NAME**  
 Burlington Lakeshore  
 Veterinary Hospital

**REFERRING VET**  
 Dr. Aziz

**INVOICE**  
 27165

**DATE**  
 10/27/22

**INTERPRETATION OF THE FINDINGS & FURTHER RECOMMENDATIONS**

The cause of the murmur is multifactorial with both pulmonic and aortic abnormalities appreciated. First, is severe presumably valvular pulmonic stenosis. The degree of obstruction is severe based upon the appearance of the right heart and velocity through the region. The pulmonic valve is not extensively visualized, and an exact level of the stenosis cannot be determined. Regardless, there is mild to moderate right heart enlargement, which is highly concerning in such a young dog. There is also subaortic and



**PATIENT**

Bauer Wolf

**SPECIES**

Canine

**BREED**

Rottweiler

**SEX**

Male Intact

**AGE**

3 months

**WEIGHT**

20.3lbs

**INTERPRETED BY**

Maggie Machen Lamy,  
DVM DACVIM  
(Cardiology)

**IMAGING PERFORMED BY**

Kelly Reschny, RVT

**HOSPITAL NAME**

Burlington Lakeshore  
Veterinary Hospital

**REFERRING VET**

Dr. Aziz

**INVOICE**

27165

**DATE**

10/27/22

aortic stenosis, with a moderately increased pressure gradient. The most concerning issue in this region is marked aortic insufficiency is present, which will lead to volume and pressure overload over time. Trace MR and TR are hemodynamically insignificant comparatively; however, both should be monitored going forward. No other congenital abnormalities are visualized; however, these are certainly not ruled out. **Any animal with complex disease should be referred for advanced evaluation, to confirm the diagnosis and determine lifelong management.**

Depending on the level of stenosis, balloon valvuloplasty should be considered in this patient as the gold standard therapeutic option for this condition if possible and may improve long term outcome and delay onset of clinical signs (including exertional syncope and right-sided congestive heart failure). If surgery is not elected, this patient's condition will likely limit lifespan, with many severe PS cases developing CHF by mid-life. Regardless, medical management with atenolol is recommended to decrease heart rate and lessen the obstruction. This should not be instituted until a minimum of 4 months of age. Monitor for development of associated clinical signs (collapse, abdominal distention, cough, labored breathing). Mild exercise restriction is advised.

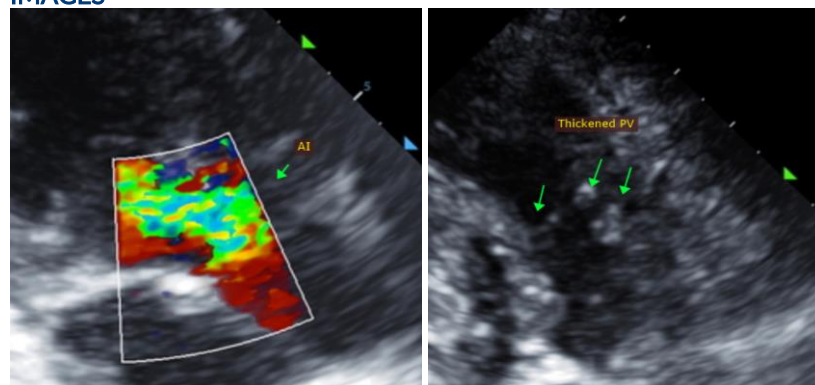
Anesthetic risk is mild to moderate at this time. Avoid heart rate stimulating drugs such as atropine or glycopyrrolate unless absolutely necessary. Avoid vasodilators such as acepromazine. Mild IV fluid restriction is advised. Cardiac protective drug choices (opioid/benzodiazepine premedication, propofol or alfaxalone induction, isoflurane gas) are recommended. Pre-oxygenate for 5-10 minutes prior to induction and recover in O2 if possible. Monitor for arrhythmias, hypotension, and hypoxia both intra and post-operatively and intervene as necessary.

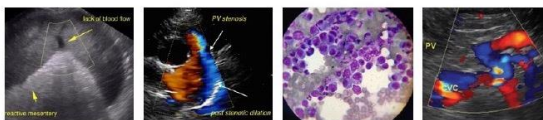
**PLAN**

Immediate referral is recommended as discussed. If declined, once 4 months of age, institute atenolol to effect: 25mg tabs, ¼ tab PO SID to start (up-titrate to desired effect). Goal is to suppress heart rate <120-140bpm even with stress/activity. Baseline ECG recommended.

If referral is declined, recommend recheck echocardiogram in 6 months to assess for progression, response to medication.

**IMAGES**





**PATIENT**

Bauer Wolf

**SPECIES**

Canine

**BREED**

Rottweiler

**SEX**

Male Intact

**AGE**

3 months

**WEIGHT**

20.3lbs

**INTERPRETED BY**

Maggie Machen Lamy,  
DVM DACVIM  
(Cardiology)

**IMAGING  
PERFORMED BY**

Kelly Reschny, RVT

**HOSPITAL NAME**

Burlington Lakeshore  
Veterinary Hospital

**REFERRING VET**

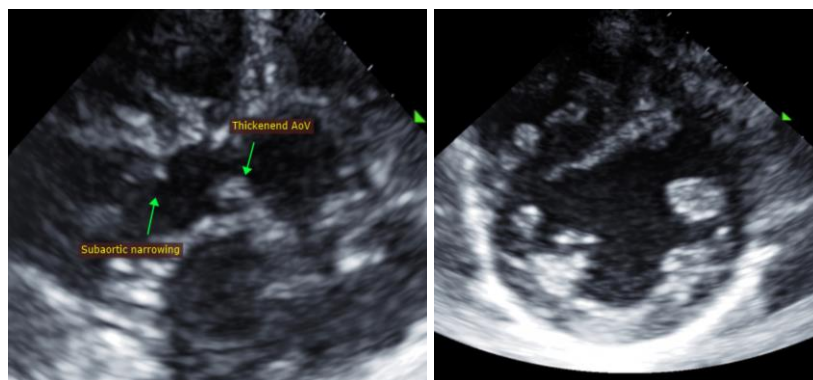
Dr. Aziz

**INVOICE**

27165

**DATE**

10/27/22



The information and recommendations provided are based on the images presented by the referring veterinarian. No evaluation can be communicated regarding pathology that was not visible in the image/video clips provided.

Thank you for this referral. This report was generated using transcription software, and minor dictation errors may be present. If the clinical or image interpretation does not parallel your findings or if I can be of any further assistance, please contact me.

Maggie Machen Lamy, DVM  
Diplomate of the American College of Veterinary Internal Medicine (Cardiology)  
info@sonopath.com